

# Morphometry of the pancreas in human foetuses

Elżbieta Krakowiak-Sarnowska, Piotr Flisiński, Michał Szpinda, Jan Sarnowski,  
Paweł Lisewski, Mariusz Flisiński

*Department of Normal Anatomy of the Ludwik Rydygier Collegium Medicum in Bydgoszcz,  
the Nicolaus Copernicus University in Toruń, Poland*

[Received 26 February 2004; Revised 2 November 2004; Accepted 2 November 2004]

*With the use of conventional anatomical dissection, radiography, digital and statistical analysis, morphometry and skeletopy of the pancreas was carried out in 60 human foetuses of both sexes (28 female, 32 male) between the 17<sup>th</sup> and 40<sup>th</sup> week of intrauterine life. The material was fixed in a 10% formalin solution. The age of the foetuses was determined by crown-rump (CR) length measurement on the basis of the Iffy et al. tables. Photographic documentation was made and then digitally processed in the Computer Image Digital Analysis System. The following parameters were taken into account: the length and width of 3 parts of the pancreas, namely the head, corpus and tail. Additionally, radiograms were made to obtain a projection of the gland on the vertebral column. Development of the pancreas was correlated with the age of the foetuses calculated on the basis of crown-rump (CR) length measurements. The correlation coefficient with CR was 0.998 for the pancreas length, 0.709 for the width of the head, 0.703 for the width of the corpus and 0.712 for the width of tail. Gender dimorphism was not found ( $p > 0.05$ ) with regard to the morphometry of the pancreas. In the material under examination the pancreas did not change its position in relation to the vertebral column. The head projected on the vertebral column in the range Th<sub>12</sub>–L<sub>2</sub> (most frequently L<sub>1</sub>–L<sub>2</sub>), the corpus on Th<sub>12</sub>–L<sub>2</sub> and the tail on Th<sub>11</sub>.*

**Key words:** skeletopy, pancreatic parameters

## INTRODUCTION

The rapid development of research techniques, both invasive and non-invasive, has enabled diagnostics to be carried out from the beginning of intrauterine life [3, 4]. An early diagnosis of foetal anomaly implicates obstetric proceedings (such as intrauterine surgery or delivery of the pregnancy by caesarean section) and the selection of optimal treatment methods for mother and foetus [15]. Morphometric and skeletopic examinations of the pancreas in the prenatal period will contribute to a better knowledge of the state of the foetus and the choice of appropriate medical management [10]. The objective of this research was to recognise

the developmental regularity of the pancreas with respect to its measurements and position in relation to the vertebral column (skeletopy).

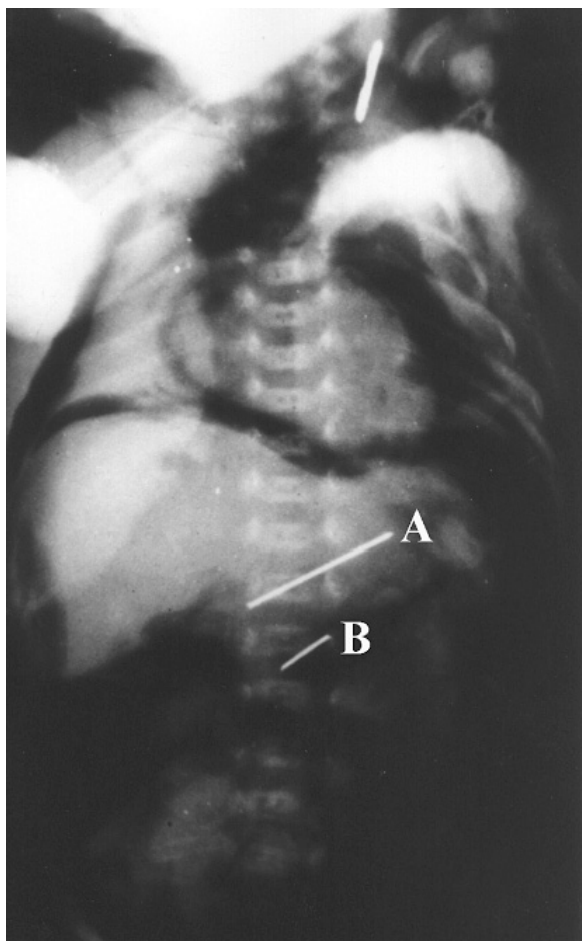
## MATERIAL AND METHODS

The examination covered 60 pancreases from human foetuses of both sexes (28 female, 32 male) between the 17<sup>th</sup> and 40<sup>th</sup> weeks of prenatal life, which came from spontaneous abortions or still births. The material was fixed in a 10% formalin solution. The age of the foetuses was determined by crown-rump (CR) length measurements on the basis of the Iffy et al. tables [6, 7].

In order to expose the pancreas, the abdominal integument was cut and the gastrocolic ligament then released. Photographic documentation was made and then digitally processed in the Computer Image Digital Analysis System. The following parameters were taken into account: the length and width of 3 parts of the pancreas, namely the head, corpus and tail. In order to obtain a projection of the pancreas on the vertebral column, we marked the upper and lower edges of the pancreas with a pins and then made radiograms (Fig. 1). Statistical analysis was made of the material collected on the basis of Student's t-test for two independent variables ( $p < 0.01$ ) for gender dimorphism and for two dependent variables for the dynamics of development.

### RESULTS

The development of the pancreas was correlated with the age of the foetuses as calculated on the basis of crown-rump (CR) length measurements.



**Figure 1.** Radiogram showing the skeletopy of the pancreas: A — superior border of the pancreas; B — inferior border of the pancreatic head.

The correlation coefficient with CR was 0.998 for the pancreas length, 0.709 for the width of the head, 0.703 for the width of the corpus and 0.712 for the width of tail. Gender dimorphism was not found ( $p > 0.05$ ) with regard to the morphometry of the pancreas. Pancreas localisation in the skeletopic analysis was stable. The head projected on the vertebral column in the range Th<sub>12</sub>-L<sub>2</sub> (most frequently L<sub>1</sub>-L<sub>2</sub>), the corpus on Th<sub>12</sub>-L<sub>2</sub> and the tail on Th<sub>11</sub>.

The results drawn up by statistical analysis are presented in Tables 1-4.

**Table 1.** Developmental dynamic of the length of the pancreas

Age		Sex		Length of the pancreas [mm]			
Months	Weeks	F	M	Max.	Min.	Mean	SD
V	17-20	3	19	23.0	10.5	15.99	4.35
VI	21-24	15	6	28.0	13.0	20.67	3.93
VII	25-28	5	6	26.5	19.0	23.09	0.99
VIII	29-32	1	1	28.3	26.4	27.35	1.90
IX	33-36	2	0	33.0	32.8	32.90	0.14
X	37-40	2	0	36.6	25.8	31.20	7.63

**Table 2.** Developmental dynamic of the width of the pancreatic head

Age		Sex		Width of the pancreatic head [mm]			
Months	Weeks	F	M	Max.	Min.	Mean	SD
V	17-20	3	19	13.00	3.70	6.17	1.99
VI	21-24	15	6	13.90	4.00	7.78	2.30
VII	25-28	5	6	15.00	4.50	9.13	3.06
VIII	29-32	1	1	9.20	7.70	8.45	1.06
IX	33-36	2	0	11.00	9.00	10.00	1.41
X	37-40	2	0	15.80	11.10	13.45	3.32

**Table 3.** Developmental dynamic of the width of the pancreatic body

Age		Sex		Width of the pancreatic body [mm]			
Months	Weeks	F	M	Max.	Min.	Mean	SD
V	17-20	3	19	6.6	2.1	3.40	1.16
VI	21-24	15	6	6.5	2.7	4.40	1.01
VII	25-28	5	6	5.5	3.0	4.25	1.12
VIII	29-32	1	1	7.3	6.0	6.65	0.91
IX	33-36	2	0	6.2	6.0	6.10	0.14
X	37-40	2	0	8.5	6.3	7.40	1.55

**Table 4.** Developmental dynamic of the width of the pancreatic tail

	Age		Sex		Width of the tail of the pancreas [mm]			
	Months	Weeks	F	M	Max.	Min.	Mean	SD
V		17–20	3	19	5.80	1.60	2.90	0.98
VI		21–24	15	6	8.60	2.30	4.26	1.53
VII		25–28	5	6	6.00	3.20	4.20	0.92
VIII		29–32	1	1	4.30	3.80	4.05	0.35
IX		33–36	2	0	5.20	5.00	5.10	0.14
X		37–40	2	0	7.20	5.90	6.55	0.91

## DISCUSSION

The process of pancreas formation from two buds, one dorsal and one abdominal, is completed before the 16<sup>th</sup> week of intrauterine life [1, 2, 11, 14, 16]. This has been confirmed by the author's own research. Developmental abnormalities of the pancreas were not observed in the material examined. This does not correspond to Kozu's observations [10]. In this work, gender dimorphism ( $p > 0.05$ ) was not stated. The correlation between the length and width of the pancreas and the age of the fetuses is confirmed by the results obtained by other authors. With the use of ultrasonography Siegel et al. [15] examined the pancreases of 273 children, confirming a higher correlation between length and width with age, rather than with the weight, height or surface of the body. With the use of USG in pregnant women, Hata et al. [3, 4] examined the length of the pancreases of fetuses and also found a high degree of correlation with gestational age. In recent years computed tomography (CT) has been used for metric examinations of the pancreas in the postnatal period [7, 13]. With the use of computed tomography Schulz et al. [13] measured the length and width of the pancreas and its volume (96 cases), while Heuck et al. [5] described relationships between the age of the patient (20–80 years) and morphological changes in the CT image of the pancreas. The works of Kolmannskog et al. [8, 9], which compared USG and CT examinations, emphasise the low repeatability of measurements in both methods. However, the parameters of the pancreas fall within the limits of the normal measurements of the pancreas. Thus, in this context, examination of the pancreas by autopsy appears irreplaceable. According to Privezentseva [12], the projection of the pancreas on the vertebral

column in adults showed a similar position to the foetal material examined. The discussion is restricted by the absence of skeletopic foetal relationships of the pancreas in the available publications. The present author's examinations show that during foetal development the pancreas occupies a constant position in relation to the vertebral column.

## CONCLUSION

The conclusion of our study is that the length and width of the head, corpus and tail parameters of the pancreas are correlated with foetal age. The skeletopy of the pancreas was stable between the 17<sup>th</sup> and 40<sup>th</sup> weeks of intrauterine life.

## REFERENCES

1. Akhtemiichuk JT (1997) The embryotopographic interrelations of the pancreas with the organs of the retroperitoneal space. *Morfologia*, 112: 75–79.
2. Debas HT (1997) Molecular insights into the development of the pancreas. *Am J Surg*, 174: 227–231.
3. Hata K, Hata T, Kitao M (1988) Ultrasonographic identification and measurement of the foetal pancreas in utero. *J Gynecol Obstet*, 26: 61–68.
4. Hata T, Deter RL (1992) A review of foetal organ measurements obtained with ultrasound: normal growth. *J Clin Ultrasound*, 20 (3): 155–174.
5. Heuck A, Maubach PA, Reiser M, Feuerbach S, Allgayer B, Lukas P, Kahn T (1987) Age-related morphology of the normal pancreas on computed tomography. *Gastrointest Radiol*, 12 (1): 18–22.
6. Iffy L, Jakobovits A, Westlake W, Wingate M, Caterini H, Konofsky R, Menduke H (1975) The rate of growth of Caucasian embryos and fetuses between the 6<sup>th</sup> and 20<sup>th</sup> weeks of gestation. *Pediatrics*, 56: 2–8.
7. Iffy L, Lavenhar M, Kaminetzky HA, Jongbloet PH, Wingate MB (1978) The effect of maternal age, parity foetal sex and season upon early intrauterine development. *J Gynecol Obstet*, 16: 210–214.
8. Kolmannskog F, Swensen T, Vant MH, Larsen S (1982) Computed tomography and ultrasound of the normal pancreas. *Acta Radiol Diagn Stockh*, 23 (5): 443–451.
9. Kolmannskog F, Larsen S, Swensen T, Larsen T (1983) Reproducibility and observed variation at computed tomography and ultrasound of the normal pancreas. *Acta Radiol Diagn Stockh*, 24 (1): 21–25.
10. Kozu T, Suda K, Toki R (1995) Pancreatic development and anatomical variation. *Gastrointest Endosc Clin*, 5: 1–4.
11. Park HW, Chae YM, Shin TS (1992) Morphogenic development of the pancreas in the staged human embryo. *Yonsei Med J*, 33: 104–109.
12. Privezentseva TV (1973) Roentgenologic anatomy of the pancreas. *Vestn Rentgenol Radiol*, 48 (2): 56–61.

13. Schulz H. G, Christou A, Gursky S, Rother R (1986) Computerized tomography studies of normal morphology and volumetry of parenchymatous epigastric organs in humans. *Anat Anz*, 162 (1): 1–12.
14. Sedlar T W (1993) *Embriologia lekarska* Langmana. Med Tour Press Int, Warszawa.
15. Siegel MJ, Martin KW, Worthington JL (1987) Normal and abnormal pancreas in children — US studies. *Radiology*, 165 (1): 15–18.
16. Tadokoro H, Koza T, Toki F, Kobayashi M, Hayashi N (1997) Embryological fusion between the ducts of the ventral and dorsal primordia of the pancreas occurs in two manners. *Pancreas*, 14: 407–412.